

## Short Communication

# Recurrent Fatal Necrotizing Fasciitis due to *Streptococcus pyogenes* in a Child with Hereditary Sensory and Autonomic Neuropathy Type IV

Canan Kuzdan, Ahmet Soysal\*, Gülşen Altinkanat<sup>1</sup>,  
Burak Aksu<sup>1</sup>, Güner Söyletir<sup>1</sup>, and Mustafa Bakir

Department of Pediatrics, Division of Pediatric Infectious Diseases and  
<sup>1</sup>Department of Microbiology, Marmara University Hospital, Istanbul, Turkey

(Received December 6, 2010. Accepted December 27, 2010)

**SUMMARY:** Although necrotizing fasciitis (NF) is a rapidly progressive infection, recurrent NF is very rare. Herein we report a rare case of recurrent NF due to *Streptococcus pyogenes*. A 12-year-old female with hereditary sensory and autonomic neuropathy (HSAN) type IV presented with fever and swelling on her left knee. NF was diagnosed and she was treated successfully. Two years later she was readmitted with NF of the right knee and limb. Despite treatment, progressive tissue necrosis developed and proximal femur amputation was performed. Eight months following the second attack she was readmitted with NF of her left knee and her entire leg. Despite a wide surgical debridement and antibiotic treatment, the clinical status of the patient failed to improve and she subsequently died. Although many conditions have been reported to be predisposing factors for NF, this is the first report of an association between HSAN type IV and recurrent NF due to *S. pyogenes*. We recommend antibiotic prophylaxis for patients with NF due to *S. pyogenes*, especially for those with predisposing factors.

Necrotizing fasciitis (NF) is a rapidly progressive, deep-seated bacterial infection of the subcutaneous soft tissue that may involve any area of the body. It often follows a fulminant course and has a high mortality rate of 25–75% (1). There are very few reports of recurrent NF in the literature.

Herein we report the case of a child with three *Streptococcus pyogenes*-related NF attacks in a 3-year period.

A 12-year-old girl with hereditary sensory and autonomic neuropathy type IV (HSAN IV) first presented with a fever of 39°C and swelling of her left knee 3 years ago. The swelling on her left knee spread to her left thigh in 24 h and the skin of the swollen area became dark and gangrenous. She underwent major tissue debridement, and cultures from the wound and surgically debrided tissue yielded *S. pyogenes*. She was treated successfully with wide surgical debridement and ampicillin/sulbactam plus clindamycin for 21 days, after which time she was discharged without any sequelae. Two years later she presented with fever and swelling and a dark area of skin on her right knee. Her extremities were cold and peripheral perfusion was poor. She had an axillary temperature of 39°C, tachycardia, hypotension, and tachypnea. Examination of her right thigh revealed extensive swelling, induration, and edema, with darkened skin and an area of gangrenous skin around her right knee (Fig. 1). Magnetic resonance imaging (MRI) of the right thigh showed massive effusion within the muscles and the right knee joint, increased muscle intensity, cortical loss in the bones, especially the tibia, in the axial T2-weighted images, and displacement of the femoral and tibial epiphyses in the sagittal T2-weighted images (Fig. 2). Blood, joint aspira-

tion fluid, and surgically debrided tissue cultures grew *S. pyogenes*. NF was diagnosed on the basis of the clinical and microbiological findings. Ampicillin/sulbactam plus clindamycin were started in addition to multiple fresh frozen plasma transfusions. Intravenous immunoglobulin (0.4 g/kg/day) was administered for 5 days for the adjunctive treatment of sepsis. Subsequent to stabilization of her vital

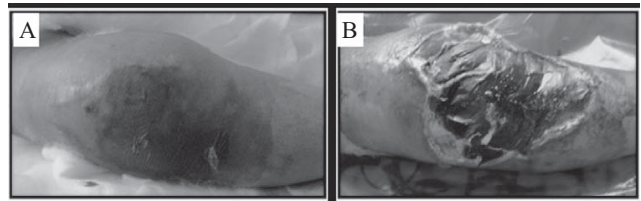


Fig. 1. Extensive swelling, induration, and edema with darkened and gangrenous skin of the right thigh.

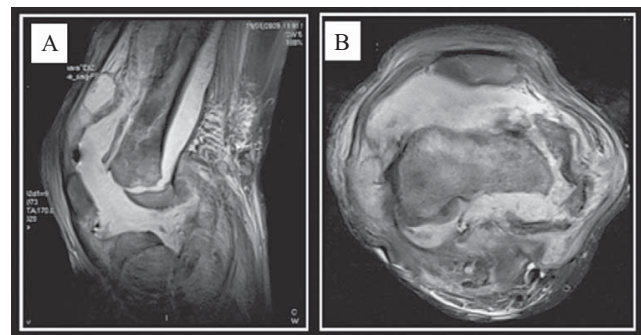


Fig. 2. (A) Epiphysis appeared to be displaced. Moreover tibia appeared to be displaced laterally on the sagittal T2-weighted image. (B) Massive effusion appearing within the muscles and within the knee joint, increased intensity of the muscles on wide-spread loss in the cortex in the bones, especially more prominent in the tibia were determined on the axial T2-weighted image.

\*Corresponding author: Mailing address: T.C. Sağlık Bakanlığı Marmara Üniversitesi Eğitim ve Araştırma Hastanesi, Çocuk Sağlığı ve Hastalıkları Anabilim Dalı, Çocuk Enfeksiyon Hastalıkları Bilim Dalı, oda no: 2829, Fevzi Çakmak Mahallesi Mimar Sinan Caddesi No: 41 Üstköy, Pendik, İstanbul, Turkey. Tel: +90-216-6254625, E-mail: asoysal@marmara.edu.tr

signs, the patient underwent wide surgical debridement of all necrotic tissue and extensive fasciotomy. Hyperbaric oxygen therapy was initiated simultaneously. Proximal femur amputation was carried out due to the progression of tissue necrosis. Eight months after the second NF attack she presented again with fever as well as swelling and erythema of both of her knees and entire left leg. Her clinical picture was similar to the previous attack, with toxic appearance, poor peripheral perfusion, hypotension, and tachycardia. Dopamine and dobutamine infusions were started after volume expansion. Ampicillin/sulbactam plus clindamycin were initiated in addition to multiple transfusions of fresh frozen plasma and intravenous immunoglobulin (0.4 g/kg/day) for 5 days. Debridement of all necrotic tissue was performed. She developed severe respiratory failure on the first day of treatment and was supported by mechanical ventilation. *S. pyogenes* was isolated from both blood and surgically debrided tissue culture. Despite wide surgical debridement and antibiotic treatment, the clinical status of the patient failed to improve and she died of septic shock.

Genomic fingerprinting of *S. pyogenes* isolated during the last two episodes was performed using arbitrarily primed polymerase chain reaction (AP-PCR). Total bacterial DNA was extracted from isolates using the Qiagen mini kit. ERIC-2 (5'-AAGTAAGTGACTGGGGTGAGCG-3') and the M13 universal primer (5'-TTATGTAAAACGACGGCCAGT-3') were used for PCR amplification as described elsewhere (11–13). PCR amplicons were analyzed by gel electrophoresis in a 1% agarose gel containing ethidium bromide (0.5 µg/ml) at 100 V/cm, detected by UV transillumination, and photographed using a digital imaging system (Vilber-Lourmat, Marne La Vallee, France). Although the isolate from the first episode was not available for AP-PCR, it was shown that the strains responsible for the last two NF attacks were identical (Fig. 3).

NF rarely occurs in childhood. Indeed, the annual incidence of NF has been reported as 0.08 cases per 100,000 children, with most of the lesions located on the trunk (2). NF can be divided into two main categories depending on the bacteriological agents involved. Thus, the NF in our patient was consistent with type 2, which is caused by a single agent, in this case group A streptococcus (GAS), and usually involves the extremities and limbs. These lesions can be complicated by septic shock, known as streptococcal toxic shock syndrome, as occurred in our patient (3).

Recurrent NF is very rare. Only seven cases have been reported in the PubMed database (4–10). In each of these previously reported cases, the episodes of NF occurred years apart, were attributed to different organisms, and the number of NF episodes was never more than two, whereas in the present case we described three NF episodes due to the same organism, *S. pyogenes*. This is therefore the first report of a recurrent NF attack due to the same strain of *S. pyogenes* in the English literature.

Many conditions including a history blunt trauma, varicella infection, injected drug use, a penetrating injury such as laceration, surgical procedures, childbirth, burns, and perhaps usage of nonsteroidal anti-inflammatory drugs, have been reported to be predisposing factors for NF (1). The predisposing factors in the above-mentioned series of seven recurrent NF patients included diabetes mellitus, arteriosclerosis, obesity, hypertension, prior irradiation therapy, steroid therapy, C4 deficiency, and ObTape device placement (4–10). The predisposing factor for NF in our case was HSAN

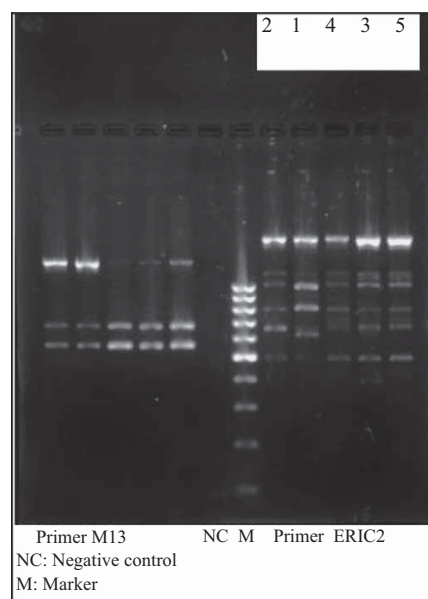


Fig. 3. Arbitrarily primed polymerase chain reaction (AP-PCR) analysis with primer ERIC-2 and M13 universal primer of 5 isolates of *Streptococcus pyogenes* during last 2 episodes. Lanes 1 to 5 were clinical isolates of *S. pyogenes*. Lanes 2 to 5 corresponded to the second attack, lane 1 corresponded to the first attack. Banding patterns were considered to be identical on the basis of band numbers and matching positions of all major bands. Small differences in major band intensities or loss of faint bands were ignored.

IV, an autosomal recessive disorder that is also known as congenital insensitivity to pain with anhidrosis. The profound loss of a pain sensation leads to injuries and self-mutilation, thereby facilitating bacterial invasion of the skin barrier and subsequent soft-tissue and skeletal infection. HSAN IV was not described as a predisposing factor in any of the previous cases (14).

Surgical exploration is the only way to confirm a suspected diagnosis of NF. Prompt surgical exploration both facilitates early debridement and allows material for subsequent culture to be obtained (15). Imaging studies may support the diagnosis, but they should not delay surgical intervention. Emergent and broad-ranging surgical debridement is critical and may need to be repeated immediately and frequently as delays in surgery are commonly associated with increased mortality. Furthermore, antibiotic therapy is ineffective in the absence of surgical debridement. In patients with suspected group A streptococcal infection, the antibiotic regimen should include intravenous penicillin and clindamycin, whereas in patients with polymicrobial infections, a  $\beta$ -lactam/ $\beta$ -lactamase inhibitor combination, such as ampicillin/sulbactam or piperacillin/tazobactam, should be considered (1). Supportive therapy includes careful fluid management, pain control, and management of multisystemic organ failure.

The role of hyperbaric oxygen therapy is controversial, although some authors have reported a reduction in mortality, morbidity, and the need for repeated debridement in up to two-thirds of cases (16). Patients who survive may require amputation, skin grafting, or reconstructive surgery. Intravenous immunoglobulin can neutralize the “superantigen” activity of bacterial exotoxins and have an opsonic effect against the surface M protein of GAS as well as a general anti-inflammatory effect (17). NF-related mortality ranges from 25 to 75%, and amputation may be necessary for in-

fection control in 22.5% of patients (1,18). It is well known that continuous antibiotic prophylaxis is recommended for patients who have suffered an acute rheumatic fever attack due to group A streptococcal pharyngitis in order to prevent recurrence (19). However, there is no data regarding the prevention of recurrence in patients who have suffered a previous GAS-related NF attack. In light of this, we propose that continuous antibiotic prophylaxis should be considered in patients with a previous NF attack due to *S. pyogenes*, especially those with predisposing factors for the development of NF.

**Conflict of interest** None to declare.

## REFERENCES

1. Teglund, A.N. and Low, D.E. (2008): Myositis, Pyomyositis, and Necrotizing Fasciitis. p. 464–474. In S.S. Long, L.K. Pickering and C.G. Prober (eds.), Principles and Practice of Pediatric Infectious Diseases. 3rd ed. Churchill Livingstone, Elsevier Inc., Philadelphia.
2. Fustes-Morales, A., Gutierrez-Castrellon, P., Duran-Mckinster, C., et al. (2002): Necrotizing fasciitis: report of 39 pediatric cases. Arch. Dermatol., 138, 893–899.
3. Chelsom, J., Halstensen, A., Haga, T., et al. (1994): Necrotizing fasciitis due to group A streptococci in western Norway. Incidence and clinical features. Lancet, 344, 1111–1115.
4. Rardin, C.R., Moore, R., Ward, R.M., et al. (2009): Recurrent thigh abscess with necrotizing fasciitis from a retained transobturator sling segment. J. Minim. Invasive Gynecol., 16, 84–87.
5. Wong, C.H., Tan, S.H., Kurup, A., et al. (2004): Recurrent necrotizing fasciitis caused by methicillin-resistant *Staphylococcus aureus*. Eur. J. Clin. Microbiol. Infect. Dis., 23, 909–911.
6. Kumar, P.D. (2001): Recurrent necrotizing fasciitis in complement C4 deficiency. Ann. Intern. Med., 135, 635.
7. Richardson, D. and Schmitz, J.P. (1997): Chronic relapsing cervicofacial necrotizing fasciitis: case report. J. Oral Maxillofac. Surg., 55, 403–408.
8. Nakayama, J. and Busse, R. (2010): An analysis of vulvar necrotizing fasciitis in the unique and ethnically diverse Hawaiian population. Hawaii. Med. J., 69, 13–16.
9. Kobayashi, Y., Yasuba, H., Yamashita, K., et al. (2005): A case of successful medical treatment for necrotizing fasciitis of the chest wall with diabetic nephropathy. J. Jpn. Respir. Soc., 43, 160–164 (in Japanese).
10. Adelson, M.D., Joret, D.M., Gordon, L.P., et al. (1991): Recurrent necrotizing fasciitis of the vulva. A case report. J. Reprod. Med., 36, 818–822.
11. Raymond, J., Schlegel, L., Garnier, F., et al. (2005): Molecular characterization of *Streptococcus pyogenes* isolates to investigate an outbreak of puerperal sepsis. Infect. Control Hosp. Epidemiol., 26, 455–461.
12. Seppälä, H., He, Q., Osterblad, M., et al. (1994): Typing of group A streptococci by random amplified polymorphic DNA analysis. J. Clin. Microbiol., 32, 1945–1948.
13. Liu, P.Y. and Wu, W.L. (1997): Use of different PCR-based DNA fingerprinting techniques and pulsed-field gel electrophoresis to investigate the epidemiology of *Acinetobacter calcoaceticus*-*Acinetobacter baumannii* complex. Diagn. Microbiol. Infect. Dis., 29, 19–28.
14. Rosemberg, S., Marie, S.K. and Kliemann, S. (1994): Congenital insensitivity to pain with anhidrosis (hereditary sensory and autonomic neuropathy type IV). Pediatr. Neurol., 1, 50–56.
15. Stevens, D.L., Tanner, M.H., Winship, J., et al. (1989): Severe group A streptococcal infections associated with a toxic shock-like syndrome and scarlet fever toxin A. N. Engl. J. Med., 321, 1–7.
16. Jallali, N., Withey, S. and Butler, P.E. (2005): Hyperbaric oxygen as adjuvant therapy in the management of necrotizing fasciitis. Am. J. Surg., 189, 462–466.
17. Basma, H., Norrby-Teglund, A., McGeer, A., et al. (1998): Opsonic antibodies to the surface M protein of group A streptococci in pooled normal immunoglobulins (IVIG): potential impact on the clinical efficacy of IVIG therapy for severe invasive group A streptococcal infections. Infect. Immun., 66, 2279–2283.
18. Wong, C.H., Chang, H.C., Pasupathy, S., et al. (2003): Necrotizing fasciitis: clinical presentation, microbiology and determinants of mortality. J. Bone Joint Surg. Am., 85-A, 1454–1460.
19. Gerber, M.A. (2007): Group A streptococcus. p. 1135–1144. In Kliegman, R.M., Behrman, R.E., Jenson, H.B., et al. (eds.), Nelson Textbook of Pediatrics. 18th ed. Saunders Elsevier, Philadelphia.